


**PATIENT PRESENTING CLINICAL SIGNS**

Koda Kilp History: Recently diagnosed diabetic. Vomiting, anorexia, regurgitating.

**SPECIES** Physical Examination: N/A.

Canine Urinalysis: N/A.

CBC: Neutrophilia.

**BREED** Serum Biochemistry: Elevated ALP activity, glucose, urea, amylase and lipase. Abnormal cPL.

Rottweiler Radiographic Findings: N/A.

**SEX ULTRASONOGRAPHIC EXAMINATION OF THE ABDOMEN**

MN **Urinary System**

**Age** Full urinary bladder with a normal thickness and appearance of the wall. Small amount of floating hyperechogenic sediment present. No uroliths evident.

5 years

Normal trigone area, proximal urethra (1 cm), and iliac blood vessels.

**WEIGHT**

106 #

Iliac lymphadenomegaly (left 0.9 x 4.4 cm, right 0.5 x 1.6 cm) with a normal shape and echogenic appearance. Ureters not visualized.

**INTERPRETED BY** Renomegaly (left 8.9 cm, right 9.8 cm) with increased echogenic appearance, some loss of cortico-medullary differentiation, and normal pelvis and capsule.

Remo Lobetti, BVSc,  
MMedVet (Med), PhD,  
Dipl. ECVIM

**Reproductive System**

Small hypoechogenic prostate (2 cm).

**IMAGING PERFORMED BY**

Sonya Myers, DVM

**Adrenal Glands**

Normal position, shape, and echogenic appearance. Bilaterally enlarged. Left 0.89/0.64 cm, right 0.76 cm.

**HOSPITAL NAME**

Oviedo Veterinary Care  
and Emergency

**Spleen**

Normal size (2 cm) and echogenic appearance. Smooth homogenous parenchyma, regular curvilinear capsule, and normal vasculature. Small focal hypoechogenic parenchymal nodule (0.7 cm) in the body of the spleen. No evidence of inflammatory, neoplastic, infarction, or infiltrative changes noted.

**REFERRING VET**

Dr Megaly

**Liver**

**INVOICE** Enlarged with rounded edges, diffuse hyperechogenic appearance, loss of portal markings, and regular curvilinear capsule. No nodules or masses evident. Full gall bladder containing normal anechoic bile. Normal thickness and echogenic appearance of the gall bladder wall. Normal bile duct (0.3 cm).

303691

**DATE**

12/21/22


**PATIENT**
***Gastrointestinal***

Koda Kilp

Normal appearance of the stomach, duodenum, small intestine, ileo-cecal junction, and colon with no loss of layering, normal wall thickness (stomach 0.59 cm, duodenum 0.43 cm, jejunum 0.34 cm) and peristaltic activity, and no distension of the lumen. Fluid-filled stomach.

**SPECIES**

Canine

***Pancreas***
**BREED**

Rottweiler

Enlarged (right 2.2 cm) with a hypoechogenic appearance. Regular capsule. Normal echogenic appearance of the mesentery and fat surrounding the pancreas.

**SEX**

MN

**Age**

5 years

***Free Abdomen***

Mesenteric lymphadenomegaly (4.7 cm) with a normal shape and echogenic appearance. No ascites.

**WEIGHT**

106 #

**Primary Findings:**

- Hepatopathy.
- Nephropathy.
- Adrenomegaly.
- Pancreatitis.
- Lymphadenomegaly.

**INTERPRETED BY**

Remo Lobetti, BVSc,  
MMedVet (Med), PhD,  
Dipl. ECVIM

**Secondary Findings:**

- Urinary bladder sediment.
- Splenic nodule.

**IMAGING PERFORMED BY**

Sonya Myers, DVM

**HOSPITAL NAME**

Oviedo Veterinary Care  
and Emergency

**REFERRING VET**

Dr Megaly

**INTERPRETATION OF THE FINDINGS & FURTHER RECOMMENDATIONS**

The most likely etiology for the hepatopathy would be secondary to the diabetes and/or the pancreatitis, with reactive, hepatitis (viral, bacterial, toxins, leptospirosis), and infiltrative neoplasia; differential diagnoses.

Etiologies for the nephropathy would be acute kidney injury (toxins, hypoxia), leptospirosis, and bacterial nephritis.

Etiologies for the adrenal glands would be disease stress and Cushing's disease.

Etiologies for the lymph nodes would be reactive, lymphadenitis, and infiltrative neoplasia.

**INVOICE**

303691

Further assessment would be urinalysis, urine culture, *Leptospira* serology/PCR, and FNA cytology of the liver. Once the pancreatitis has resolved and the diabetes stabilized, adrenal function testing could be considered.

**DATE**

12/21/22

Specific therapy would be dependent on an etiological diagnosis. Initial therapy would be fluids, correction of electrolyte anomalies, anti-emetics, opioid analgesics, insulin, and low-fat intestinal diet.



**PATIENT**  
 Koda Kilp

**IMAGES**  
 Stomach

**SPECIES**

Canine

**BREED**

Rottweiler

**SEX**

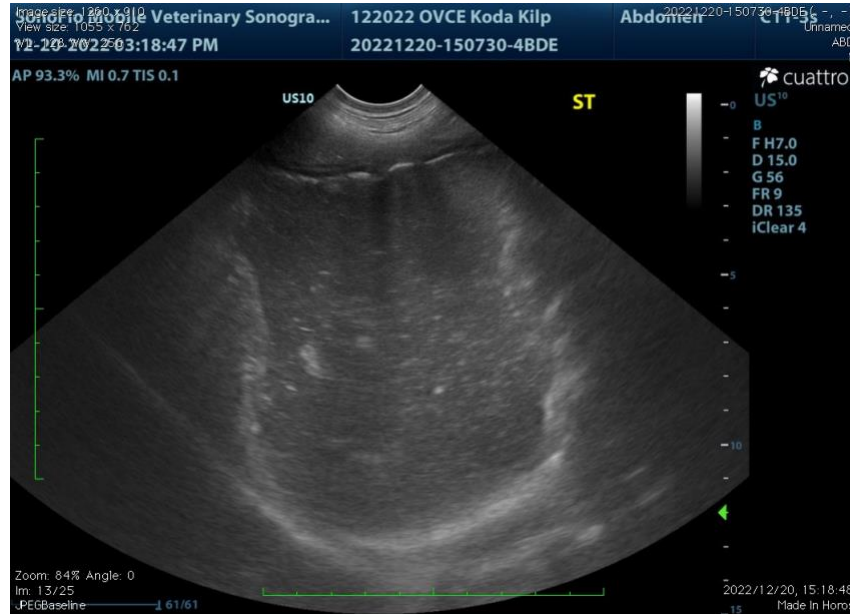
MN

**Age**

5 years

**WEIGHT**

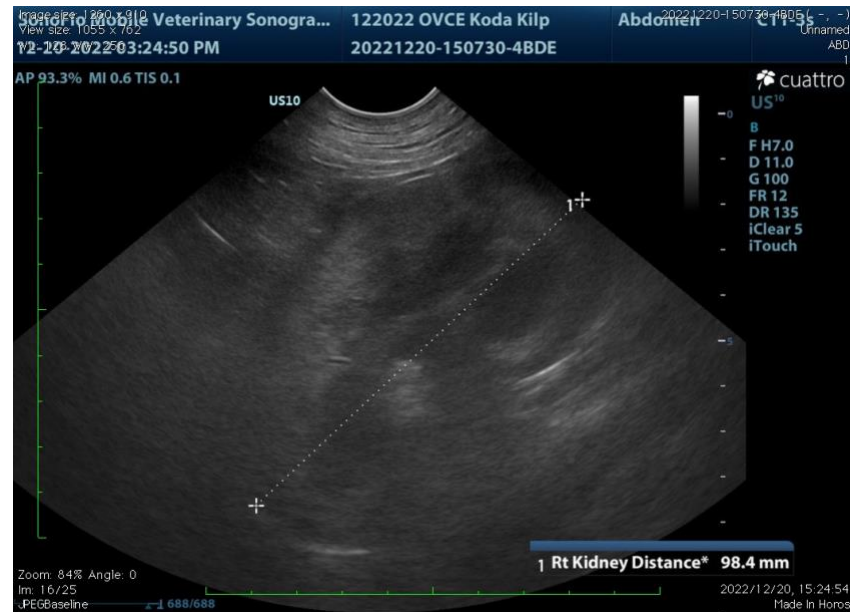106 #



**INTERPRETED BY**

Remo Lobetti, BVSc,  
 MMedVet (Med), PhD,  
 Dipl. ECVIM

**Right kidney**



**IMAGING PERFORMED BY**

Sonya Myers, DVM

**HOSPITAL NAME**

Oviedo Veterinary Care  
 and Emergency

**REFERRING VET**

Dr Megaly

**INVOICE**

303691

**DATE**

12/21/22



**PATIENT** Liver

Koda Kilp

**SPECIES**

Canine

**BREED**

Rottweiler

**SEX**

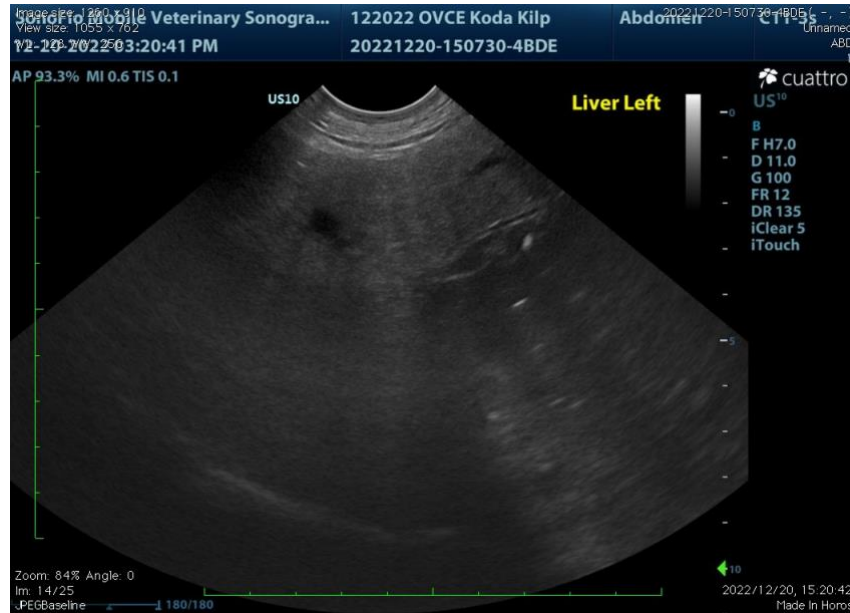MN

**Age**

5 years

**WEIGHT**

106 #



**Pancreas**

**INTERPRETED BY**

Remo Lobetti, BVSc,  
 MMedVet (Med), PhD,  
 Dipl. ECVIM

**IMAGING PERFORMED BY**

Sonya Myers, DVM

**HOSPITAL NAME**

Oviedo Veterinary Care  
 and Emergency

**REFERRING VET**

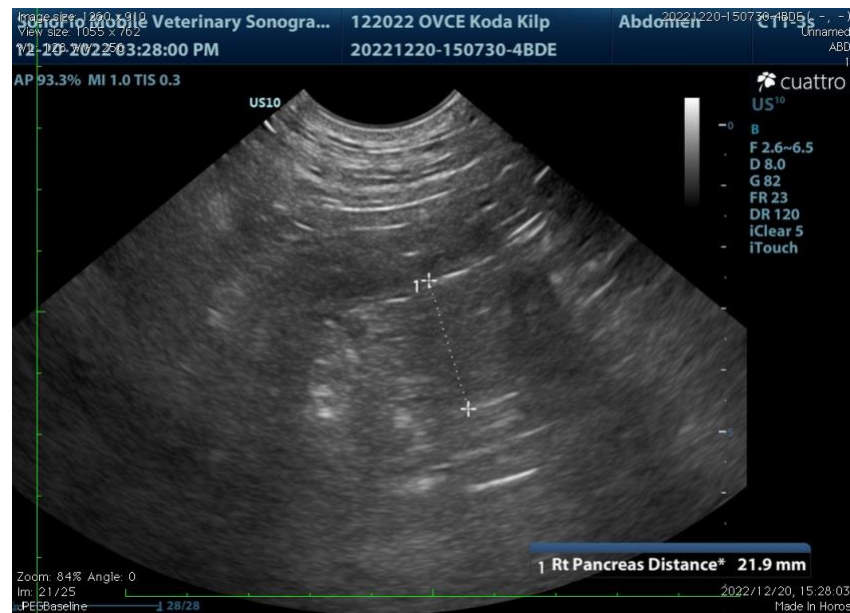Dr Megaly

**INVOICE**

303691

**DATE**

12/21/22





**PATIENT**

Iliac lymph node

Koda Kilp

**SPECIES**

Canine

**BREED**

Rottweiler

**SEX**

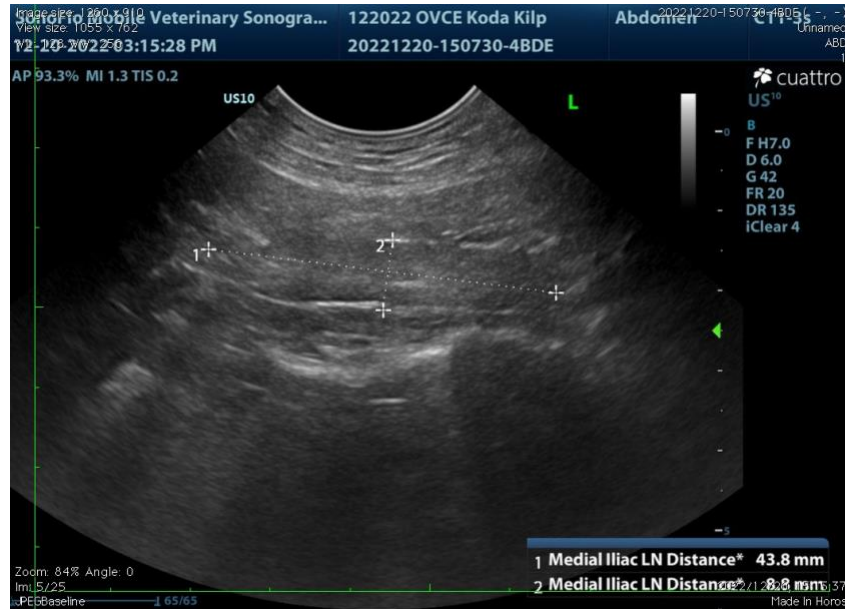MN

**Age**

5 years

**WEIGHT**

106 #



**INTERPRETED BY**

Remo Lobetti, BVSc,  
 MMedVet (Med), PhD,  
 Dipl. ECVIM

The information and recommendations provided are based on the images presented by the referring veterinarian. No evaluation can be communicated regarding pathology that was not visible in the image/video clips provided.

Thank you for this referral. If the clinical or image interpretation does not parallel your findings or if I can be of any further assistance, please contact me

**Remo Lobetti**, BVSc, MMedVet (Med), PhD, Dipl. ECVIM (Internal Medicine)  
[rlobetti@mweb.co.za](mailto:rlobetti@mweb.co.za)

**IMAGING PERFORMED BY**

Sonya Myers, DVM

**HOSPITAL NAME**

Oviedo Veterinary Care  
 and Emergency

**REFERRING VET**

Dr Megaly

**INVOICE**

303691

**DATE**

12/21/22